

# Multifocal Acquired Demyelinating Sensory and Motor Neuropathy: Report of A Case and Review of the Literature

Yu-Wan Yang, Chung-Hsiang Liu, Chon-Haw Tsai, Cheng-Chun Lee, and Shuo-Bin Jou

**Abstract-** Multifocal acquired demyelinating sensory and motor (MADSAM) neuropathy is characterized by an asymmetric multifocal pattern of motor and sensory loss, and conduction block and other features of demyelination in nerve conduction studies<sup>(1,2)</sup>. MADSAM neuropathy needs to be differentiated from chronic inflammatory demyelinating polyneuropathy (CIDP) and multifocal motor neuropathy (MMN)<sup>(1,2)</sup>. In classic CIDP, there are symmetric proximal and distal weakness, sensory deficit in both upper and lower extremities and reduced deep tendon reflex<sup>(2)</sup>. In MMN, limb weakness without sensory loss is asymmetric in the distribution of individual peripheral nerves and the weakness typically begins in the distal upper extremities. We report one patient with chronic progression of asymmetric numbness and weakness in four extremities. MADSAM neuropathy was diagnosed after extensive clinical and laboratory evaluations. It is very important to distinguish between CIDP, MADSAM neuropathy, and MMN by clinical, laboratory, and histological features because of different effective therapeutic strategies.

**Key Words:** Multifocal acquired demyelinating sensory and motor neuropathy, Asymmetric, Chronic inflammatory demyelinating polyradiculoneuropathy, Multifocal motor neuropathy

*Acta Neurol Taiwan 2004;13:24-28*

## INTRODUCTION

In 1982 Lewis and colleagues reported 5 patients with an unusual neuropathy, best described as a chronic demyelinating sensorimotor mononeuropathy multiplex<sup>(3,4)</sup>. This type of neuropathy, also referred to as the Lewis-Sumner syndrome, can be distinguished from multifocal motor neuropathy (MMN) by different clinical presentations and laboratory findings. Whether "Lewis-Sumner syndrome" is a separate nosological

entity, a focal variant of chronic inflammatory demyelinating polyneuropathy (CIDP), or a subset of MMN with sensory involvement has been debated<sup>(1,2,5-7)</sup>.

We present a middle-age man with insidious onset and slow progression of numbness and weakness in four extremities. MADSAM neuropathy was diagnosed according to clinical manifestations, electrophysiological features, and laboratory data. This is the first report of a MADSAM neuropathy in Taiwan.

From the Department of Neurology, China Medical University Hospital, Taichung, Taiwan.  
Received August 8, 2003. Revised September 10, 2003.  
Accepted November 16, 2003.

Reprint requests and correspondence to: Shuo-Bin Jou, MD, Department of Neurology, China Medical University Hospital, No. 2, Yu-Der Road, Taichung, Taiwan.  
E-mail: neuro@www.cmuh.org.tw

## CASE REPORT

This 38-year-old man experienced diminished sensation in left hand in January 2001. He denied any systemic diseases or toxic exposure. There was no pain, cramping, or fasciculations in his hands. The numbness spread from distal to proximal parts of left upper limb, and then to the other limbs. Four months later, the patient had asymmetric weakness in his distal four extremities, which interfered with his walking. Neurological examination in July 2001 revealed asymmetric distal weakness with mild muscle wasting. The motor examination using MRC scale revealed 4+ in right deltoid; 4- in right biceps, triceps, dorsal and palmar interossei and left biceps, triceps, brachioradialis, flexor carpi radialis, and abductor pollicis brevis; 4 in the other muscles. The patient had difficulty walking on toes and heels. Sensory examination revealed impaired pinprick and light touch sensations in the medial part of the bilateral forearms, and the first, second, third, and fourth fingers, and the medial part of the left leg. Triceps and ankle jerks were depressed and biceps, brachioradialis, and knee jerks were absent. The nerve conduction studies revealed asymmetric motor and sensory conduction slowing, motor conduction block, prolonged or absent F-waves, absent H-reflex, and reduced amplitude of compound muscle action potentials (CMAPs), and sensory

nerve action potentials (SNAPs) (Tables 1 and 2). The CSF study was normal, except for a marked elevation of protein (170mg/dl). The protein electrophoresis and immunoelectrophoresis of CSF and blood failed to show monoclonal gammopathy. Serum anti-GM1 antibody titer (449.1 BTU) was below low-cutting (1000 BTU: cut off). The anti-nuclear antibody and antibody for HIV were negative. Fasting blood glucose was 84 mg/dl; HbA1c, 5.4% (Normal: 4.6 to 6.5%); ESR 7 mm/hr. (Normal: 0-15 mm/hr).

MADSAM neuropathy was diagnosed. The patient received prednisolone (50 mg per day), and symptoms were markedly improved after 4 months treatment. The motor examination after one year's prednisolone treatment showed MRC 4+ in right deltoid, biceps, triceps, dorsal and palmar interossei and left biceps, triceps, brachioradialis, flexor carpi radialis, and abductor pollicis brevis. The patient could walk with a swagger but had difficulty walking on toes and heels. Repeated nerve conduction study repeated in December 2002 (Table 3) revealed mildly improved conduction velocities of motor nerves.

## DISCUSSION

In chronic acquired demyelinating polyneuropathy, it is important to differentiate MADSAM neuropathy from

**Table 1.** Nerve conduction studies in April, 2001

Nerve stimulated	Stimulation site	Recording site	Amplitude (motor = mV; sensory = $\mu$ V)		Latency (msec)		Conduction velocity (m/sec)		F-wave latency (msec)		H-reflex latency (msec)	
			RT	LT	RT	LT	RT	LT	RT	LT	RT	LT
Median (m)	Wrist	APB	12.1	9.7	3.6	3.8			NR	37.5		
	Elbow	APB	4.3	7.1	9.5	8.4	39	52.2				
Ulnar (m)	Wrist	ADM	9.6	9.3	3.2	3.1			36.1	30.8		
	Below elbow	ADM	4.3	6.2	7.7	7.8	51.1	50				
	Above elbow	ADM	4.3	5.1	9	9.3	61.5	53.3				
Median (s)	Wrist	Index finger	8.6	5	2.5	3	60	48.7				
Ulnar (s)	Wrist	Little finger	NR	1.1	NR	2.8	NR	45.4				
Tibial (m)	Ankle	AH	9.7	8.7	5.1	4.8			64.1	70.9	41.5	44.5
	Popliteal fossa	AH	3.8	2.3	15.8	16	37.9	35				
Peroneal (m)	Ankle	EDB	5.9	4.7	4.3	6.1	56.8	41.6				
	Below fibula	EDB	3.5	2.9	12.3	13.8	39.4	42.9				
	Lateral popliteal fossa	EDB	3.1	2	14.4	15.8	38.1	40				
Sural (s)	Calf	Posterior ankle	4.6	9.1	3.1	3	45.2	46.7				

m: motor study; s: sensory study; RT: right; LT: left; NR: no response; APB: abductor pollicis brevis; ADM: abductor digiti minimi; AH: abductor hallucis; EDB: extensor digitorum brevis.

Note: All sensory latencies are peak latencies. F-wave and H-reflex latencies represent the minimum latency.

Table 2. Nerve conduction studies in July, 2001

Nerve stimulated	Stimulation site	Recording site	Amplitude (motor = mV; sensory = $\mu$ V)		Latency (msec)		Conduction velocity (m/sec)		F-wave latency (msec)		H-reflex latency (msec)	
			RT	LT	RT	LT	RT	LT	RT	LT	RT	LT
			Median (m)	Wrist	APB	5.8	8.2	3.8	3.4			36.6
	Elbow	APB	1.4	4.7	12.5	8.2	27.4	47.9				
Ulnar (m)	Wrist	ADM	6.1	5.5	3.4	2.9			45.8	40.5		
	Below elbow	ADM	2.3	4.5	9.1	7.2	40.4	51.2				
	Above elbow	ADM	2.2	3.8	10.5	8.8	57.1	50				
Median (s)	Wrist	Index finger	4.1	1.7	2.8	2.9	53.6	51.7				
Ulnar (s)	Wrist	Little finger	0.8	1.3	2.3	2.5	56.5	52				
Tibial (m)	Ankle	AH	6.2	4.1	4	4.5			66.2	57.8	NR	NR
	Popliteal fossa	AH	1.2	0.9	15.5	17.4	35.9	31				
Peroneal (m)	Ankle	EDB	4.7	3.1	3.7	4.6			76.3	89.6		
	Below fibula	EDB	1.6	1.4	12.2	13.4	37.6	36.4				
	Lateral popliteal fossa	EDB	1.1	0.8	14.8	16	30.8	30.8				
Sural (s)	Calf	Posterior ankle	3.7	5.3	3.2	3.4	43.8	41.2				

Abbreviations as in Table 1.

Table 3. Nerve conduction studies in December, 2002

Nerve stimulated	Stimulation site	Recording site	Amplitude (motor = mV; sensory = $\mu$ V)		Latency (msec)		Conduction velocity (m/sec)		F-wave latency (msec)		H-reflex latency (msec)	
			RT	LT	RT	LT	RT	LT	RT	LT	RT	LT
			Median (m)	Wrist	APB	10.8	8.7	3.7	3.9			36.2
	Elbow	APB	9.9	8.4	10.1	8.6	36.7	50				
Ulnar (m)	Wrist	ADM	10	9.4	3.2	3.2			38.6	33.7		
	Below elbow	ADM	3.8	8.1	8.7	8	42.7	49				
	Above elbow	ADM	3.6	7.7	10.5	9.8	44.4	44.4				
Median (s)	Wrist	Index finger	9.8	7	2.8	2.8	53.6	53.6				
Ulnar (s)	Wrist	Little finger	NR	NR	NR	2.8	NR	48.2				
Tibial (m)	Ankle	AH	10.9	9.2		4.2	4.5		54.3	60	46.8	51.8
	Popliteal fossa	AH	6.4	5.4	14.6	16	38.5	34.8				
Peroneal (m)	Ankle	EDB	3.3	2.7	4.2	5			58.8	58.8		
	Below fibula	EDB	2.6	1.9	12.7	12.7	37.1	40.9				
	Lateral popliteal fossa	EDB	2.3	1.8	15.2	15.3	32	30.8				
Sural (s)	Calf	Posterior ankle	1.6	5.9	3.6	3.4	38.9	41.2				

Abbreviations as in Table 1.

CIDP and MMN<sup>(8)</sup>. Classic CIDP is characterized by a symmetric proximal and distal phenotype. When diagnostic criteria for CIDP were initially proposed, weakness of proximal and distal limbs was a mandatory inclusion criterion<sup>(2,9,10)</sup>. CIDP may begin insidiously and evolves slowly, attaining its maximum severity after several months or even a year or longer<sup>(2)</sup>. CIDP was separated from acute inflammatory polyneuropathy by Austin in 1958 based on a chronic relapsing course, enlargement of nerves, and responsiveness to steroids<sup>(11)</sup>. The symptoms and signs of CIDP may be asymmetrical initially and have ascending involvements. But it usually

progresses slowly to symmetric weakness, loss of deep tendon reflex, and impaired sensation in hands and feet<sup>(2,12,13)</sup>. Antecedent infections can be identified far less regularly in patients with CIDP than those with acute inflammatory demyelinating polyneuropathy (AIDP)<sup>(14)</sup>. Elevated concentration of CSF protein and evidence of demyelination on electrodiagnostic examination are found in most patients with CIDP<sup>(1,2,12)</sup>. The pathophysiology of CIDP is still unclear, but an autoimmune mechanism is proposed due to the likely responsiveness of immunomodulating treatments of CIDP<sup>(2,9,10,12,13,15)</sup>. The efficacy of corticosteroids<sup>(2,13,16)</sup>, plasma exchange<sup>(17,18)</sup>,

and IVIg<sup>(19,21)</sup> in treating CIDP have been demonstrated in several randomized controlled trials.

In contrast to CIDP, multifocal motor neuropathy (MMN) shows an asymmetrical weakness and muscle atrophy, typically in the distribution of individual peripheral nerves without sensory involvement<sup>(1,12,13,22-24)</sup>. MMN with a clinical picture of mononeuritis multiplex and electrophysiologic evidence of persistent motor conduction block (MCB)<sup>(1,2,12,13)</sup> is considered an acquired immune-mediated demyelinating motor polyneuropathy<sup>(2,13,15)</sup>. The diagnosis of MMN usually relies on the presence of MCBs. High titers of anti-GM1 antibodies are often detected in the serum of patients with MMN<sup>(2,12,13)</sup>. IVIg<sup>(1,2,15)</sup> and cyclophosphamide<sup>(1,2,13,14)</sup> are effective treatment for the majority of patients with MMN.

Lewis and his colleagues reported in 1982 five patients exhibiting different clinical and neurophysiologic features from 35 patients with classical CIDP<sup>(4)</sup>. The major features that separate MADSAM neuropathy from typical CIDP are the electrophysiological findings<sup>(3)</sup> and favorable responses to plasma exchange, prednisone, or IVIg. Similar to CIDP, CSF protein content is increased in 60-80% of patients with MADSAM neuropathy<sup>(1,3,5,7,14)</sup>. On the other hand, polyclonal IgM antibodies against GM1 may be detected in 40-80% of MMN patients, but difficult to detect in CIDP and MADSAM neuropathy<sup>(1,3,5,7,14)</sup>. In MADSAM neuropathy, MMN, and CIDP, the nerve conduction studies show features of demyelination, such as conduction block, temporal dispersion, prolonged distal latencies, slow conduction velocities, and absent or prolonged F-wave latencies in one or more motor nerves<sup>(1-3)</sup>. MADSAM neuropathy is different from MMN due to sensory nerves are involved and different from CIDP due to conspicuous asymmetric multiple nerves involvement.

60-70% of patients with MADSAM neuropathy showed improvement after IVIg treatment, lasting for several months. Such response is similar to the those of CIDP and MMN<sup>(1,3,5,7,14,15)</sup>. The alternative treatment was corticosteroids. Unlike MMN but similar to CIDP, 50-70% of patients with MADSAM neuropathy have shown improvement with corticosteroid treatment<sup>(1,2,5,7)</sup>. However, only less than 3% of patients with MMN

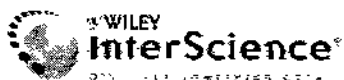responded to corticosteroid<sup>(22)</sup>.

Our patient had asymmetric multifocal demyelinating neuropathy with conduction block in nerve conduction study, elevated CSF protein content, low anti-GM1 antibody titer, and a good response to steroid. These features fulfill the diagnostic criteria for MADSAM neuropathy. Prednisolone treatment seemed to be effective. It is important to distinguish MADSAM neuropathy from CIDP and MMN.

## REFERENCES

1. Saperstein DS, Amato AA, Wolfe GI, et al. Multifocal acquired demyelinating sensory and motor neuropathy: the Lewis-Sumner syndrome. *Muscle Nerve* 1999;22:560-6.
2. Saperstein DS, Katz JS, Amato AA, et al. Clinical spectrum of chronic acquired demyelinating polyneuropathies. *Muscle Nerve* 2001;24:311-24.
3. Parry GJ. Are multifocal motor neuropathy and Lewis-Sumner syndrome distinct nosologic entities? *Muscle Nerve* 1999;22:557-9.
4. Lewis RA, Sumner AJ, Brown MJ, et al. Multifocal demyelinating neuropathy with persistent conduction block. *Neurology* 1982;32:958-64.
5. Gorson KC, Ropper AH, Weinberg DH, et al. Upper limb predominant, multifocal chronic inflammatory demyelinating polyneuropathy. *Muscle Nerve* 1999;22:758-65.
6. Lewis RA. Multifocal motor neuropathy and Lewis-Sumner syndrome: two distinct entities. *Muscle Nerve* 1999;22:1738-9.
7. Oh SJ, Claussen GC, Kim DS. Motor and sensory demyelinating mononeuropathy multiplex (multifocal motor and sensory demyelinating neuropathy): a separate entity or a variant of chronic inflammatory demyelinating polyneuropathy? *J Periph Nerv Syst* 1997;2:362-9.
8. Van den Berg-Vos RM, Van den Berg LH, Franssen H, et al. Multifocal inflammatory demyelinating neuropathy: a distinct clinical entity? *Neurology* 2000;54:26.
9. Barohn RJ, Kissel JT, Warmolts JR, et al. Chronic inflammatory demyelinating polyradiculoneuropathy. Clinical characteristics, course, and recommendations for diagnostic criteria. *Arch Neurol* 1989;46:878-84.
10. Dyck PJ, Lais AC, Ohta M, et al. Chronic inflammatory polyradiculoneuropathy. *Mayo Clin Proc* 1975;50:621-37.

11. Austin JH. Observations on the syndrome of hypertrophic neuritis (the hypertrophic interstitial radiculoneuropathies). *Medicine* 1956;35:187.
12. Sander HW, Latov N. Research criteria for defining patients with CIDP. *Neurology* 2003;60:S8-S15.
13. Koski CL. Therapy of CIDP and related immune-mediated neuropathies. *Neurology* 2002;59:S22-7.
14. Victor M, Ropper AH. Diseases of the peripheral nerves. In: Adams and Victor's Principles of Neurology 2001: 1410-3.
15. Van Doorn PA, Garssen MP. Treatment of immune neuropathies. *Curr Opin Neurol* 2002;15:623-31.
16. Dyck PJ, O'Brien PC, Oviatt KF, et al. Prednisone improves chronic inflammatory demyelinating polyradiculoneuropathy more than no treatment. *Ann Neurol* 1982; 11:136-41.
17. Dyck PJ, Daube J, O'Brien PC, et al. Plasma exchange in chronic inflammatory demyelinating polyradiculoneuropathy. *N Engl J Med* 1986;314:461-5.
18. Hahn AF, Bolton CF, Pillary N, et al. Plasma-exchange therapy in chronic inflammatory demyelinating polyneuropathy: a double-blind, sham-controlled, cross-over study. *Brain* 1996;1055-66.
19. Dyck PJ, Litchy WJ, Kratz KM, et al. A plasma exchange versus immune globulin infusion trial in chronic inflammatory demyelinating polyradiculoneuropathy. *Ann Neurol* 1994;36:838-45.
20. Hahn AF, Bolton CF, Zochodne D, et al. Intravenous immunoglobulin treatment in chronic inflammatory demyelinating polyneuropathy. A double-blind, placebo-controlled, crossover study. *Brain* 1996;119:1067-77.
21. Mendell JR, Barohn RJ, Kissel JT, et al. Intravenous immunoglobulin in untreated patients with chronic inflammatory demyelinating polyneuropathy. *Neurology* 2000; 54(Suppl 3):A212.
22. Auer RN, Bell RB, Lee MA. Neuropathy with onion bulb formations and pure motor manifestations. *Can J Neurol Sci* 1989;16:194-7.
23. Chaudhry V. Multifocal motor neuropathy. *Semin Neurol* 1998;18:73-81.
24. Chaudhry V, Corse AM, Cornblath DR, et al. Multifocal motor neuropathy: response to human immune globulin. *Ann Neurol* 1993;33:237-42.



[Home](#) / [Medical, Veterinary and Health Sciences](#) / [Neurology](#)



## Muscle & Nerve

Volume 22 Issue 5, Pages 560 - 566

Published-Online: 26 Apr 1999

Copyright © 2009 Wiley Periodicals, Inc., A Wiley Company

- [Get Sample Copy](#)
- [Recommend to Your Librarian](#)
- [Save journal to My Profile](#)
- [Set E-Mail Alert](#)
- [Email this page](#)
- [Print this page](#)
- [RSS web feed \(What is RSS?\)](#)

Earn CME credit at  
[www.aanem.org](http://www.aanem.org)



[Go to Society Site](#)

[Save Article to My Profile](#) [Download Citation](#)

[< Previous Abstract](#) | [Next Abstract >](#)

[Abstract](#) | [References](#) | [Full Text: PDF \(Size: 148K\)](#) | [Related Articles](#) | [Citation Tracking](#)

### Main Article

#### Multifocal acquired demyelinating sensory and motor neuropathy: The Lewis-Sumner syndrome

David S. Saperstein, MD<sup>1</sup>, Anthony A. Amato, MD<sup>2\*</sup>, Gil I. Wolfe, MD<sup>1</sup>, Jonathan S. Katz, MD<sup>3</sup>, Sharon P. Nations, MD<sup>1</sup>, Carlayne E. Jackson, MD<sup>2</sup>, Wilson W. Bryan, MD<sup>1</sup>, Dennis K. Burns, MD<sup>4</sup>, Richard J. Barohn, MD<sup>1</sup>

<sup>1</sup>Department of Neurology, University of Texas Southwestern Medical Center, Dallas, Texas, USA

<sup>2</sup>Department of Medicine, Division of Neurology, University of Texas Health Science Center at San Antonio, 7703 Floyd Curl Drive, San Antonio, Texas 78284-7883, USA

<sup>3</sup>Department of Neurology, Stanford University, Palo Alto, California, USA

<sup>4</sup>Department of Pathology, University of Texas Southwestern Medical Center, Dallas, Texas, USA

\*Correspondence to Anthony A. Amato, Department of Medicine, Division of Neurology, University of Texas Health Science Center at San Antonio, 7703 Floyd Curl Drive, San Antonio, Texas 78284-7883, USA

#### Keywords

chronic inflammatory demyelinating polyneuropathy; conduction block; Lewis-Sumner syndrome; mononeuropathy multiplex; multifocal motor neuropathy

#### Abstract

We report 11 patients with multifocal acquired demyelinating sensory and motor (MADSAM) neuropathy, defined clinically by a multifocal pattern of motor and sensory loss, with nerve conduction studies showing conduction block and other features of demyelination. The clinical, laboratory, and histological features of these patients were contrasted with those of 16 patients with multifocal motor neuropathy (MMN). Eighty-two percent of MADSAM neuropathy patients had elevated protein concentrations in the cerebrospinal fluid, compared with 9% of the MMN patients ( $P < 0.001$ ). No MADSAM neuropathy patient had elevated anti-GM<sub>1</sub> antibody titers, compared with 56% of MMN patients ( $P < 0.01$ ).

In contrast to the subtle abnormalities described for MMN, MADSAM neuropathy patients had prominent demyelination on sensory nerve biopsies. Response to intravenous immunoglobulin treatment was similar in both groups ( $P = 1.0$ ). Multifocal motor neuropathy patients typically do not respond to prednisone, but 3 of 6 MADSAM neuropathy patients improved with prednisone. MADSAM neuropathy more closely resembles chronic inflammatory demyelinating polyneuropathy and probably represents an asymmetrical variant. Given their different clinical patterns and responses to treatment, it is important to distinguish between MADSAM neuropathy and MMN. © 1999 John Wiley & Sons, Inc. *Muscle Nerve* 22: 560-566, 1999

Accepted: 6 November 1998

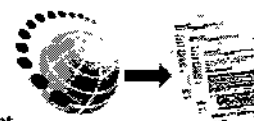
### Related Articles

- Find other [articles](#) like this in Wiley InterScience
- Find articles in Wiley InterScience written by any of the [authors](#)

Wiley InterScience is a member of CrossRef.



[Request Reprint](#)



# Multifocal acquired demyelinating sensory and motor neuropathy

From Ganfyd

(Redirected from LSS)

**Multifocal acquired demyelinating sensory and motor neuropathy (MADSAM, Lewis-Sumner syndrome, LSS)**<sup>[1]</sup> is a multifocal but asymmetric demyelinating neuropathy with rare axonal degeneration<sup>[2]</sup>. It is an inflammatory polyradiculoplexoneuropathy that shares features observed in chronic inflammatory demyelinating polyneuropathy (CIDP) and multifocal motor neuropathy (MMN). It needs to be distinguished from MMN as this has treatment implications as MNN does not ever respond to steroids and may get worse. Short term response with intravenous immunoglobulin is likely to be similar to plasma exchange.<sup>[3][4]</sup> Corticosteroids and immunosuppressive agents might be considered.

## References

<p><b>Web Resources for Multifocal acquired demyelinating sensory and motor neuropathy</b></p> <p><b>Relevant Clinical Literature</b> ICD-10 search</p> <p><b>Pubmed on Multifocal acquired demyelinating sensory and motor neuropathy RCT with Multifocal acquired demyelinating sensory and motor neuropathy</b> from Pubmed</p> <p><b>Systematic reviews of Multifocal acquired demyelinating sensory and motor neuropathy</b> from Pubmed</p> <p><b>Multifocal acquired demyelinating sensory and motor neuropathy in N Eng J Med, Lancet, JAMA, BMJ</b> from Pubmed</p> <p><b>Multifocal acquired demyelinating sensory and motor neuropathy in Cochrane Collaboration</b> from Pubmed</p> <p><b>TRIP Database on Multifocal acquired demyelinating sensory and motor neuropathy</b></p> <p><b>Google Scholar on Multifocal acquired demyelinating sensory and motor neuropathy</b></p> <p><b>Bandolier on Multifocal acquired demyelinating sensory and motor neuropathy</b></p> <p><b>UK Guidance</b></p> <p><b>NeLH on Multifocal acquired demyelinating sensory and motor neuropathy</b></p> <p><b>NHS Evidence on Multifocal acquired demyelinating sensory and motor neuropathy</b></p> <p><b>Centre for Reviews and Dissemination databases -DARE &amp; NHS EED (evaluates reliability of research)</b></p> <p><b>Nice Guidance on Multifocal acquired demyelinating sensory and motor neuropathy</b></p> <p><b>Prodigy Guidance on Multifocal acquired demyelinating sensory and motor neuropathy</b></p> <p><b>Other Wikis</b></p> <p><b>Medpedia on Multifocal acquired demyelinating sensory and motor neuropathy (Less technical, good quality control)</b></p> <p><b>Wikipedia on Multifocal acquired demyelinating sensory and motor neuropathy (Less technical, ? quality control)</b></p>
--

- ↑ Saperstein DS, Amato AA, Wolfe GI, Katz JS, Nations SP, Jackson CE, Bryan WW, Burns DK, Barohn RJ. Multifocal acquired demyelinating sensory and motor neuropathy: the Lewis-Sumner syndrome. Muscle & nerve. 1999

May; 22(5):560-6.

2. ↑ Viala K, Renié L, Maisonobe T, Béhin A, Neil J, Léger JM, Bouche P. Follow-up study and response to treatment in 23 patients with Lewis-Sumner syndrome. *Brain : a journal of neurology*. 2004 Sep; 127(Pt 9):2010-7.(Link to article – subscription may be required.)
3. ↑ Comi G, Nemni R, Amadio S, Galardi G, Leocani L. Intravenous immunoglobulin treatment in multifocal motor neuropathy and other chronic immune-mediated neuropathies. *Multiple sclerosis (Houndmills, Basingstoke, England)*. 1997 Apr; 3(2):93-7.
4. ↑ DNUK posting (membership required).

Retrieved from "[http://www.ganfyd.org/index.php?](http://www.ganfyd.org/index.php?title=Multifocal_acquired_demyelinating_sensory_and_motor_neuropathy)

[title=Multifocal\\_acquired\\_demyelinating\\_sensory\\_and\\_motor\\_neuropathy](http://www.ganfyd.org/index.php?title=Multifocal_acquired_demyelinating_sensory_and_motor_neuropathy)"

Categories: [Neurology](#) | [Neuropathies](#)

---

<p><b>Ganfyd is for healthcare professionals!</b> Please read the disclaimer. If you are unwell and looking for advice please see your own doctor or contact the emergency healthcare services as appropriate.</p>
--

- This page was last modified on 6 October 2008, at 21:43.
- Content is available under [ganfyd-Attribution-NonCommercial-RegisteredMedical-ShareAlike 1.0](#).